Received: 27 July 2020 | Revised: 7 August 2020 | Accepted: 10 August 2020

DOI: 10.1111/jocd.13673

ORIGINAL CONTRIBUTION

JCD Journal of Cosmetic Dermatology WILEY

Evaluation of efficacy of QR 678 and QR678 neo hair growth factor formulation for the treatment of female pattern alopecia in patients with PCOS—A prospective study

Rinky Kapoor MD[1] | Debraj Shome MD, FRCS, (Glasgow), FACS, MBA[2] | Komal Doshi MDS[3] | Ghanshyam Patel PhD[4] | Sapna Vadera MDS[5]

[1]Department of Dermatology, Cosmetic Dermatology & Dermato-Surgery & Director, The Esthetic Clinics, Mumbai, India

[2]Department of Facial Plastic Surgery & Facial Cosmetic Surgery & Director, The Esthetic Clinics, Mumbai, India

[3]Fellow in Facial Plastic Surgery and Facial Cosmetic Surgery, The Esthetic Clinics, Mumbai, India

[4]Biostatistician, Veeda Clinical Research, Ahmedabad, India

[5]Fellow Facial Plastic Surgery and Facial Cosmetic Surgery, The Esthetic Clinics, Mumbai, India

Correspondence
Dr. Debraj Shome, Department of Facial Plastic Surgery & Facial Cosmetic Surgery, The Esthetic Clinics, Mumbai 400101, India.
Email: debraj.shome@theestheticclinic.com

Abstract

Background: Hair is an essential identity of women. Femininity, sexuality, attractiveness, and personality are symbolically linked to a woman's hair. Female pattern hair loss is found in 20%-30% of patients with polycystic ovary syndrome (PCOS).

Aim: The aim of the present study was to evaluate the efficacy of QR678® and QR678 Neo® therapy in the treatment of female alopecia with PCOS.

Method: A total of 20 females diagnosed with PCOS in the age 25-50 years, with complaints of female pattern alopecia with Ludwig, grades I, and II were selected for the study. At each visit, 1.5 ml solution of QR678® was injected in the scalp skin of patients. A total of eight sessions were performed at an interval of 3 week each. All the patients were evaluated with standard global photography at baseline, 4th and 8th session, and 2 months after 8th session.

Result: Marked improvement was seen in the global photographic assessment score (mean = 8) which was maintained for over 1 year. In videomicroscopic assessment, after four sessions the patients had 8.07 fewer vellus hair, 6.07 more terminal hair, and average hair shaft diameter was 0.82 μm wider. After eight sessions, they had 11.66 fewer vellus hair, 13.77 more terminal hair, and hair shaft diameter was 2.86 μm wider than at baseline.

Conclusion: Intra-dermal injections of QR 678® hair growth factor formulation is an effective option for female pattern alopecia with PCOS. This is the first of its kind study using QR678® and QR678 Neo® in PCOS patients.

KEYWORDS

androgenic alopecia, female pattern hair loss, PCOS, QR678, QR678 Neo

1 | INTRODUCTION

The perception of beauty in society is very subjective, distinctive, and innate. The hair on the scalp contributes significantly toward social and psychological health apart from having an impact on the physical appearance in our day to day life.[1]

The most prevalent endocrine disorder in the reproductive age of females is polycystic ovarian syndrome (PCOS).[2,3] PCOS is a disorder which is multifactorial polygenic and heterogeneous in origin and is characterized by oligo and/or anovulation, infertility, hyperandrogenism (biochemical and/or clinical), and polycystic ovaries.[4,5] It ranges from 4% to 21% worldwide[6,7] and from 13% to 36% in adolescents.[8-12]

Female pattern hair loss (FPHL) is the most frequent type of alopecia in women also called androgenetic alopecia (AGA).[13] The prevalence increases from 12% for women between 20 and 29 years

of age, to more than 50% for women over the age of 80 years.[14] According to Carmina E et al, FPHL is seen in approximately 20%-30% of the patients with PCOS.[15]

Many women experience adverse psychosocial effects like depression, anxiety disorder, social phobia, or paranoid disorder due to FPHL.[16,17] 52% of women were found to be having a lower quality of life as a result of hair loss, compared with 28% of men.[14] It is essential to concentrate on the psychological distress resulting from FPHL through a dedicated treatment regime as it is an integral part of the disease.

Numerous medical modalities have been advocated and used for the management of Androgenetic Alopecia. However, existing medical, surgical, and cosmetic methods for the management are restricted in techniques and outcomes. There is an ever increasing demand for newer therapeutic approaches for the management of AGA as it affects large number of patients with considerable effect on the quality of life.[18]

In 2010, Kapoor and Shome introduced a recombinant, bioengineered, hair growth formulation comprising of a combination of growth factors, called the QR678®.[17] The safety and efficacy of intra-dermal injections of QR678® has been proven for male as well as female pattern hair loss.[19]

QR678 Neo® formulation is a plant-derived polypeptide formulation which biologically mimics the action of QR678® and consists of specific concentration of Sh-Polypeptide-9 (bio-mimicking VEGF), Sh- Oligopeptide-2 (bio-mimicking IGF-1), Sh-Polypeptide-1 (bio-mimicking bFGF), Sh-Polypeptide-3 (bio-mimicking KGF), Sh-Oligopeptide-4 (bio-mimicking Thymosin β4), and copper tripeptide suspended in a sterile injectable vehicle.[19]

The safety and efficacy of the formulation were first evaluated in an animal trial, and it was proven to be relatively free from adverse effects.[19] Later on, a prospective and interventional study was carried out on 1000 patients using QR678®. Findings suggested that the formulation of multiple growth factors QR678® and QR678 Neo® is safe and equivalent in efficacy for the treatment of alopecia in both males and females.[17]

The current study aims to evaluate the efficacy of QR678® and QR678 Neo® therapy for the treatment of female pattern hair loss in patients with PCOS.

2 | MATERIAL AND METHODS

2.1 | Study design

A prospective clinical study was performed following approval from the review board of the Institutional Ethics committee. 20 female patients diagnosed with PCOS between the age of 25 and 50 years, with complaints of female pattern alopecia were shortlisted for the study. Written, signed, and informed consent was obtained from all the participants.

2.2 | Inclusion criteria

A total of 20 female participants diagnosed with PCOS, in the age-group of 25-50 years, having female pattern hair loss and falling under Ludwig's hair loss grades I and II on clinical evaluation were selected for the study (Figure 1). They had to fulfill the following criteria:

- Patients diagnosed with PCOS on hormonal evaluation and sonography.
- Patients who had not responded to a combination of topical minoxidil 5% + oral finasteride/ spironolactone/ oral contraceptives for a period of one year or more.

FPHL is evaluated with 3 distinct hair patterns:

1. Diffuse crown thinning with frontal hairline preservation: the scales used for describing these patterns are the 5-point Sinclair scale and the 3-point Ludwig scale.
2. Widening and thinning of the central part of the scalp with frontal hairline breaching, a typical Christmas tree pattern, is described using the Olsen scale.
3. Bitemporal recession associated thinning; Hamilton-Norwood scale.

We used the Ludwig's classification.

Broader Rotterdam's criteria were used with a detailed PCOS phenotype. According to which, out of the three criteria (ovulatory dysfunction, hyperandrogenism, and polycystic ovarian morphology—PCOM) two must be present to make a diagnosis of PCOS.[20,21]

Also, all patients continued their exercise and diet advice as they had been doing for control of PCOS.

2.3 | Exclusion criteria

- Complaint of hair loss for less than 6 months.
- Patients with known drug allergy, known or suspected malignant disease, hematologic and/or autoimmune diseases, Seborrheic dermatitis, or other scalp skin disease.

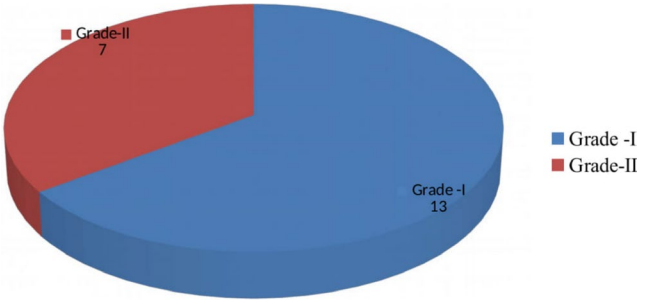

FIGURE 1 Demographic distribution of patients as per Ludwig scale

TABLE 1 Patient Self-assessment Questionnaire: Section 1

Que. No.	Question	Possible Responses (On a scale of 0-5)
1	Growth of hair	Very satisfied › Very dissatisfied
2	Amount of noticeable new hair	Very satisfied › Very dissatisfied
3	Visibility of the scalp	Very satisfied › Very dissatisfied
4	Rate of hair loss	Very satisfied › Very dissatisfied

TABLE 2 Patient Self-assessment Questionnaire: Section 2 Adverse effects

Adverse Effect	Tick the appropriate Response(if noticed)
Itchy Scalp	
Uncomfortable Pain during Injection	
Unsteadiness during injection	
Increase in hair fall	

- Pregnant and lactating women.
- Patients who have recently started or stopped the consumption of oral Finasteride/spironolactone/minoxidil and/or oral contraceptives (to alleviate the bias due to confounding factors)

Also, patients were not allowed to change hairstyle nor were allowed to color their hair throughout the treatment.

2.4 | Injection technique used for scalp

The evaluation was carried out for all the participants at baseline with standard digital photography as well as with video microscopic assessment to assess hair condition. 1.5 mL of QR678® solution was injected in the scalp skin of all the patients at each visit.

Numerous (average 60-70), small, and painless injections were given using 31-G needle through nappage technique. Injections had been given in noticeable areas with hair thinning. Injections were administered 1cm apart with 0.02 mL of volume in each injection. A total of 8 sessions were carried out, at an interval of 3 weeks each.

2.5 | Scalp assessment and evaluation

2.5.1 | Global photographic assessment

The standardized photographic technique was used to take photographs of frontal, vertex, and temporoparietal areas of the scalp at baseline, 4th and 8th session and after 2 months post 8th session. Photographs were assessed by two blinded dermatologists on the

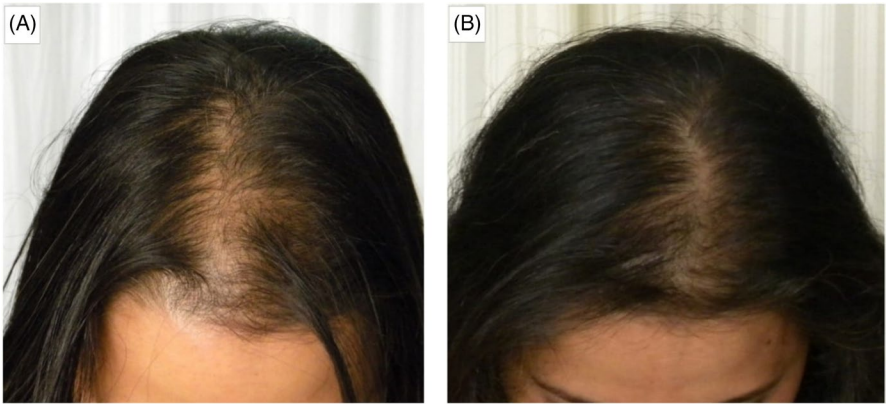

FIGURE 2 Patient 1 clinical photographs: A, Pretreatment. B, Day of 4th session

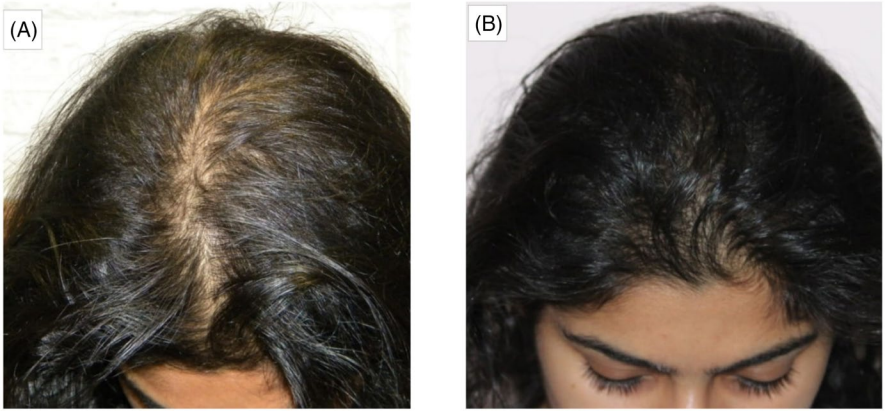

FIGURE 3 Patient 2 clinical photographs: A, Pretreatment. B, After 2 mo of 8th session

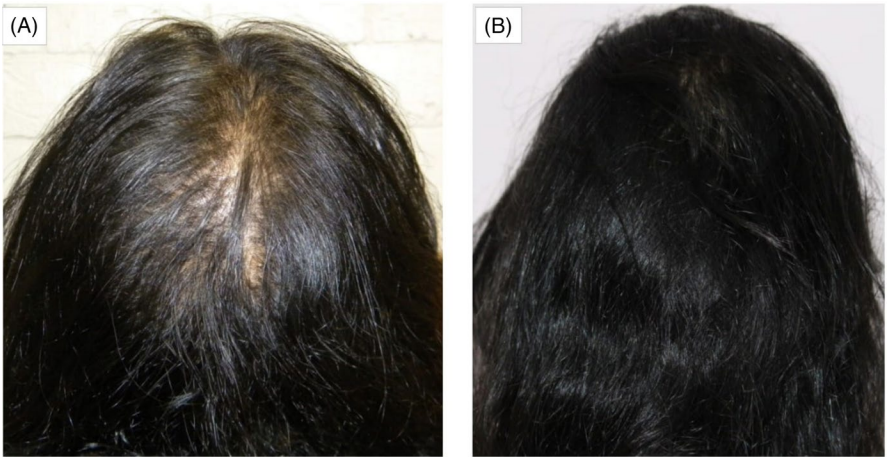

FIGURE 4 Patient 3 clinical photographs. A, Pretreatment. B, After 2 mo of 8th session

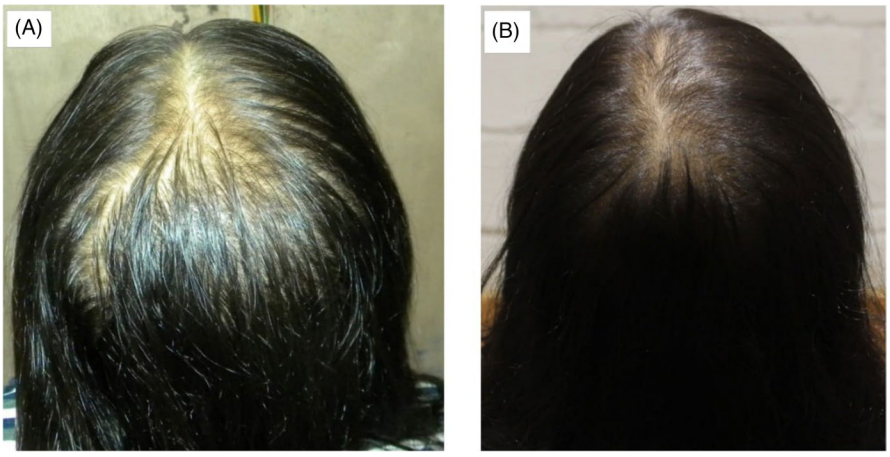

FIGURE 5 Patients clinical photograph. A, Pretreatment. B, After 2 mo of 8th session

scale 0-10, with 0 showing no growth and 10 indicating thick hair growth. The mean score was calculated and averaged.

2.5.2 | Videomicroscopic assessment

Photographs were taken using a videomicroscopic digital handheld camera. The position for each photograph was fixed at the center of the scalp, which was 20 cm behind or posterior to the glabella. Hair count per cm^2 was evaluated. Terminal hair counts (cm^2), vellus hair counts(cm^2), and shaft diameter(μm) were also evaluated using the photographs and specialized software (Trilogic company, Moscow, Russia, Tricho science version 1.5). Unpaired t test was used to assess the level of significance within the group. GraphPad software was used to calculate the results.

TABLE 3 Global Photographic Assessment by Reviewer 1 and 2 Patients showing Improvement

	QR678			
Reviewer	Baseline	4th session	8th session	Post 2 months after 8th session
Reviewer 1	5	7.5	8	8
Reviewer 2	5	7	7.5	8
Mean	5	7.25	7.75	8

2.5.3 | Patient self-assessments

A prevalidated hair growth questionnaire was given to all the patients comprising of 4 questions in section 1, where 0 indicated very dissatisfied to 5 which indicated very satisfied relating to the efficacy of treatment at the end of treatment (Table 1). In section 2, questions regarding adverse effects of the therapy were mentioned and patients were asked to mark the suitable answer (Multiple answers were also allowed) (Table 2).

TABLE 4 Global Photographic Assessment by Reviewer 1 and 2 Patients shows No improvement and worsening

	No. of Patients showing no Improvement	No. of Patients showing worsening
QR678	1	0

TABLE 5 Mean score of Vellushir count, Terminal hair counts and Hair shaft diameters, after QR678 hair injection treatment

	Mean at baseline	Mean at 4th session	Mean at 8th session	Post 2 mo after 8th session	δ	*P* value
Vellus hair counts at 20 cm	52.44	44.37	40.36	40.78	−11.66	<.001
Terminal hair counts at 20 cm	76.46	82.53	88.65	90.23	+13.77	<.001
Hair shaft diameter at 20 cm (μm)	28.78	29.60	30.67	31.64	+2.86	.004

3 | RESULTS

The prospective clinical study was conducted from October 2018 to January 2020 after seeking approval from the Institutional Ethics committee. The study included 20 female patients with PCOS from 20 to 50 years of age with FPHL who underwent hair growth therapy with QR678®.

3.1 | Global photographic assessment

The photographs were evaluated subjectively by 2 blinded reviewers (Both dermatologists) (Figures 2-5). An assessment was done on a scale of 0 to + 10.0 indicated no improvement and 10 showed maximum growth. An evaluation was done at baseline, 4th and 8th sessions and 2 months post 8th session. A baseline mean value of 5 was recorded. There was a noticeable improvement in the global assessment score post 8th session with a mean value of 8. Also, these results were maintained for over 1 year. Only 1 individual (5%) did not respond to QR678® (Table 3-4, Figure 6).

3.2 | Videomicroscopic assessment

3.2.1 | Vellus hair count

Vellus hair count for individual patients was recorded at 20 cm from the glabella. Paired *t* test was used to evaluate the results which indicated 8.07 lesser vellus hair after 4th session and 11.66 fewer vellus hair post 8th session compared with baseline. The results were statistically significant (Table 5, Figure 7).

3.2.2 | Terminal hair count

The terminal hair count was recorded at 20 cm from the glabella for each patient. Using Paired t testing, it was evaluated that compared to baseline; patients had 6.07 and 13.77 more terminal hair after fourth and eight sessions, respectively. The results were statistically significant (Table 5, Figure 7).

3.2.3 | Hair shaft diameter

The average hair shaft diameter was recorded at 20 cm from the glabella for each patient. Paired t testing showed that patients had approximately 0.82 μm and 2.86 μm wider hair shaft diameters after fourth and eight sessions compared with baseline. Results were statistically significant (Table 5, Figure 7).

3.3 | Patient self-assessment

Patients were asked to rate the questions regarding the efficacy of the treatment using a 5-point scale ranging from 0 to 5. A higher

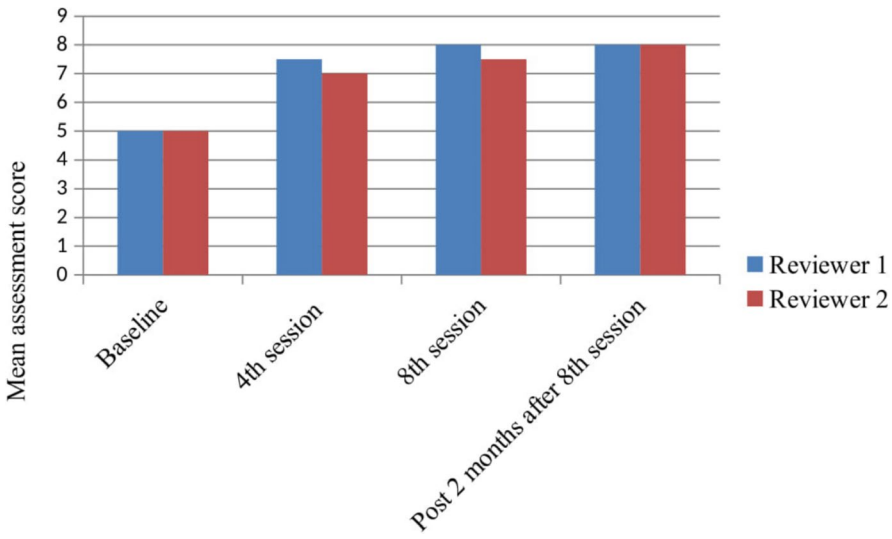

FIGURE 6 Global Photographic Assessment Score by Reviewer 1 and 2

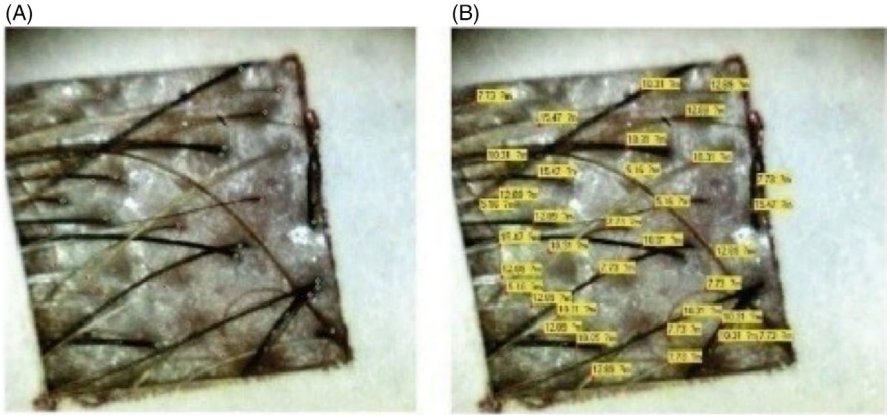

FIGURE 7 Videomicroscopic image showing vellus hair count. A, Shows a photograph of ¼ cm cutout of videomicroscopic images showing vellus hair count (in red) and terminal hair count (in green). B, Shows a photograph of ¼ cm cutout of videomicroscopic image showing assessment of mean hair shaft diameter. All measurements shown were multiplied by a factor of 2.77 for conversion to microns

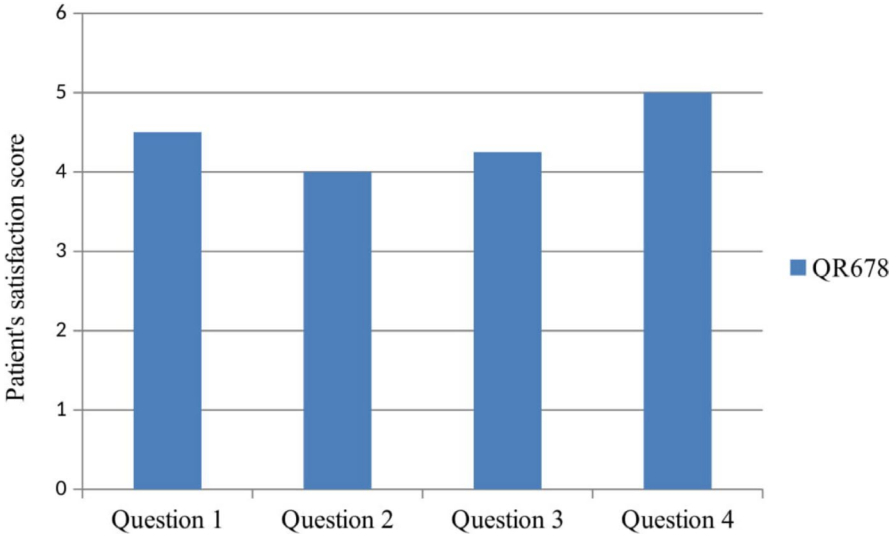

FIGURE 8 Patient Self-assessment Questionnaire

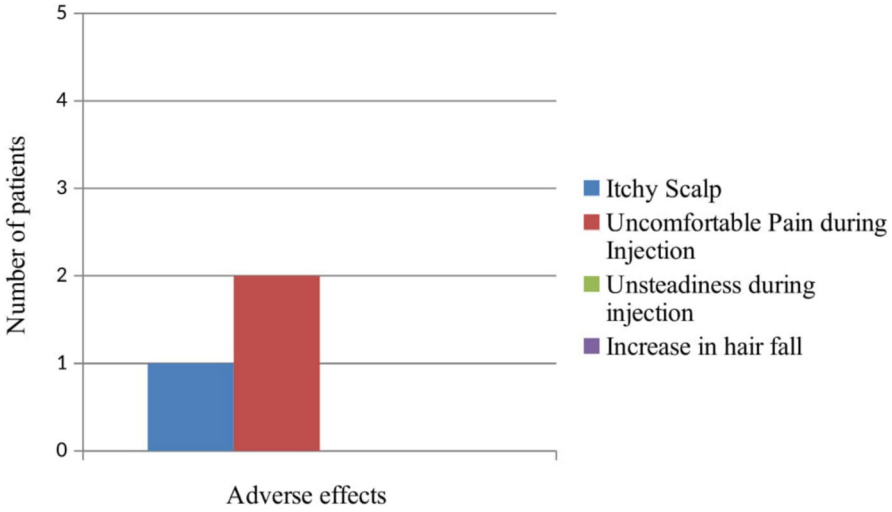

FIGURE 9 Adverse effects as evaluated at the end of the study

satisfaction score was marked by patients for the rate of hair loss (mean = 5). For the growth of new hair, the visibility of scalp, and the amount of noticeable new hair, the mean for the satisfaction score was 4.5, 4.25, and 4, respectively (Figure 8). 10% (N = 2) of patients reported uncomfortable pain during injection, and only 5% (N = 1) patients reported itchy scalp after treatment. None of the patients complained worsening of hair fall post-therapy (Figure 9).

4 | DISCUSSION

Femininity, charisma, sexuality, and individuality are most often linked to woman's hair.[22] PCOS is a condition which is associated with biochemical disturbances most commonly associated with a high level of androgens, mainly testosterone, estrogen, and luteinizing hormone (LH). Increased levels of insulin with a decreased

sex-hormone-binding globulin (SHBG) level are often accompanied.[4,23] Testosterone is transported in the body through SHBG; therefore, the adequate level of this hormone is extremely essential for the normal functioning of the system. Excess of unbound testosterone leads to acne, hirsutism, and male and female-patterned alopecia in PCOS patients.[24,25]

Approximately 50%-75% of females with PCOS have an increased level of circulating total and free dehydroepiandrosterone sulfate (DHEAS) and testosterone.[26] Also, around 70% of females with PCOS experience an increased level of serum immune-active and bioactive LH due to hyper-secretion of LH.[27]

FPHL is distinguished by the nonscarring scattered form of alopecia arising from gradual thinning of hair follicles consequently leading to decreased hair count, particularly in the frontal, central, and parietal areas of scalp.[28]

Hair loss triggers negative body image, self-depreciation, feeling of culpability, disturbed sleep cycle and daily routine, and limitation in social activities. As per the 1993 Glamour magazine survey, more than 50% of the women stated "if my hair looks good, I look attractive no matter what I'm wearing or how I look otherwise," and "if my hair isn't right, nothing else can make me feel that I look good."[14,29]

Safeguarding of a healthy hair follicle needs coordinated development and timing through the various phases of anagen, catagen, telogen, and regeneration. It is regulated by several hormones, genes, and growth factors.[15] The association between nutritional deficiencies and different types of alopecia has been proved by multiple studies.[30,31] Also, deficiencies of niacin, zinc, protein, vitamin D, biotin, fatty acids, and probably selenium were considerable factors for alopecia.[32]

Multiple growth factors have been proved to be associated with the promotion or suppression of various stages in the hair growth cycle. A wide range of growth factors have been found to be associated with hair follicle growth which includes vascular endothelial growth factor (VEGF), insulin 1-like growth factor (IGF), epidermal growth factor (EGF), wingless-related integration site (Wnt), fibroblast growth factor (FGF), noggin, copper tripeptides, and keratinocyte growth factor to name a few.[19]

A novel formulation called as QR678® (US patented 2017, Indian FDA approval 2019) was introduced by Kapoor and Shome in 2018. A QR Code means "Quick Response" which is used in medicine and the number 678 in Morse Code signifies "there is no answer." Thus, the formulation was named as QR678® which signifies "Quick Response to a disease which earlier had no answer," that is, alopecia. Previous human trials have proved it as safe and efficacious and has also confirmed on hair pull test that it significantly decrease hair fall in around 83% of patients.[19]

The Food and Drug Administration (FDA) has approved few treatment options of FPHL including topical minoxidil 2% and 5% in females, hair restoration surgery, and low-level light therapy. Treatments not approved are cyproterone acetate, spironolactone, combination oral contraceptives, flutamide, and topical estradiol.[33]

4.1 | Minoxidil solution

Minoxidil not only helps telogen hair to enter the anagen phase but also prolongs the duration of the anagen phase. There is an increase in hair count and volume with the prolonged use of minoxidil.[34] FDA approved 2% minoxidil in 1991 and a 5% minoxidil foam got approval in 2014 for once-daily application.[35] Common side effect involves scaling, irritation of scalp, dryness, itching, and/or redness.[36] Another possibility is hypertrichosis of the forehead or on the cheeks. This can be unacceptable to women.[34]

Blume-Peytavi et al compared efficacy, safety, and acceptability of 5% minoxidil topical foam (MTF) once-daily application with 2% minoxidil topical solution (MTS) twice daily for the management of androgenetic alopecia in females. 5% MTF once daily demonstrated greater experience of target area hair count and hair width by the global photographic review as compared to females in 2% MTS twice daily group, but results were nonsignificant.[37]

Another study showed mean differences in hair counts as 14.90 hairs/cm^2 and 8.11 hairs/cm^2, respectively, after using 5% and 2% minoxidil solutions.[38] Although a comparative study of 2% minoxidil with placebo in female patients demonstrated a mean difference in hair count to be 12.41 hairs/cm,[2,39] however in our study, at the end of the fourth session we found 6.07 more terminal hairs and increased to 13 at the end of the eighth session.

Treatment with minoxidil has to be pursued permanently as the hair loss begins within 3-4 months if treatment is discontinued.[40] Also, side effects like postural hypotension, urticaria, and facial hypertrichosis have been described.[41] However in our study, only one patient had itchy scalp. Other patients were free of any adverse effect. And also termination of the QR678® treatment does not show hair loss with some maintenance therapy.

Sinclair et al carried out an observational study to evaluate the combined treatment option using spironolactone and low-dose oral minoxidil with a sample size of 100 female patients. 0.25 mg minoxidil was used once daily along with 25 mg spironolactone. The hair loss severity score was reduced by 0.85 at the end of 6 months and 1.3 at the end of 12 months. The hair shedding score was reduced to a mean of 2.3 at 6 months and 2.6 at 12 months.[41] However in our study, we found highest satisfactory rate on reduced hair fall at the end of the treatment (mean score was 5).

4.2 | Finasteride

Finasteride inhibits the activity of 5α-reductase II enzyme, which is subject to catalyzing the transfer of testosterone to the more active 5 dihydrotestosterone.[13] The use of Finasteride 0.05% in a gel formula for pattern alopecia has revealed remarkable results in the past.[42] Finasteride has limited adverse effects in males; however, more controlled studies are warranted to evaluate its safety and efficacy profile in females.[34] An additional concern regarding the treatment is its contraindication in women with a history of breast cancer as it increases estrogen levels following the conversion of

testosterone to estradiol.[34] Occasional adverse effects in women include breast tenderness and increased libido. Contrary to this, QR678® does not show any side effects of treatment.[14]

Iorizzo et al evaluated the efficiency of oral Finasteride in association with an oral contraceptive (with a combination of Ethinyl estradiol and drospirenone) in the premenopausal females with FPHL. Thirty-seven female patients participated in the study. Oral Finasteride was added additionally apart from 2.5 mg/d oral of oral contraceptive. The evaluation was done using global photographic assessment, and the hair density was checked using videodermoscopy. 23 participants showed improvement as per global photography at the end of 12 months of follow-up. However, 13 patients showed no signs of improvement and deterioration was recorded for one patient.[43] In our study, after 4th session 95% of patients showed improvement (mean value 7.5) and after the 8th session mean value was 8. Only one patient showed no improvement.

4.3 | Dutasteride

Dutasteride is a 5α-reductase type I and II inhibitors. It causes inhibition of testosterone conversion into dihydrotestosterone.[34] The use of dutasteride for women is not approved by FDA.[13] However, there is evidence for successful treatment with 0.25-0.5 mg/d dose for FPHL with no adverse effects.[44] Dr Camacho used a high dose of Dutasteride (0.25 mg/dL) in postmenopausal females with FPHL and showed 60% and 80% in the first year and second year, respectively.[45]

4.4 | Laser and light treatment

A wavelength of 600-1400 nm from the infrared spectrum is used for Laser treatment of hair loss.[46] Literature shows limited evidence for the use and beneficial effects of the same. Also, the intricacies and mechanism of hair growth are unclear.[47] There is one controlled study by Leavitt M. et al presenting its efficacy in males but there are no available studies showing the results in females.[48]

4.5 | Spironolactone

Spironolactone is an aldosterone antagonist having action on androgen receptor and 5 alpha reductase inhibitor activity.[16] There have been no available RCTs demonstrating the positive effects of Spironolactone. Few case reports, open-label trials, and series have however mentioned about the efficacy of the drug.[49-52] In a case report of four patients, spironolactone decreased hair loss by 50%–62.9% with a dose of 200 mg/dL, with an increase in the number of anagen hair.[50] The anti-androgenic effects of the drug can lead to conditions like breast tenderness, menstrual irregularities, and gynecomastia.[53]

4.6 | Flutamide

It is a nonsteroidal selective anti-androgen drug that prevents androgens binding to their receptors.[54] Severe liver toxicity has been reported with the use of Flutamide. Studies have reported efficacy of the drug at a safe dose range of 62.5-250 mg d, without adverse effects.[55] However, one study reported hepatic toxicity even with a very mild dosage of Flutamide.[56] Overall, there is a scarcity of data supporting the regular use of antiandrogens in FPHL.

4.7 | Microneedling

Microneedling is a minimally invasive procedure performed with the help of rolling cylinders loaded with micro-needles, creating approximately 1.5 mm deep punctures into the stratum corneum.[57,58] Microneedling creates physical injuries through needle penetration inducing a wound healing and formation of new collagen, new growth factors along with neovascularization.[13] This technique is efficient and of low complexity that can be performed on an outpatient basis. But is much more traumatic than our technique.[18]

4.8 | Platelet-rich plasma

It is an extremely concentrated autologous plasma derivative from an individual's own blood. It contains vascular endothelial growth factor (VEGF), fibroblast growth factor (FGF), transforming growth factor-beta (TDF-β), and platelet-derived growth factor (PDGF)[59,60] These growth factors initiate the process of hair growth by the initiation of follicular stem cells to alter from dormant to an active state.[61] Though, it is a cumbersome process, as it requires patient's own blood to be collected in each visit and also requires unique apparatus.[17]

Kapoor and Shome have conducted a randomized comparative prospective study to compare the efficiency of QR678® and QR678 Neo® v/s PRP in patients of the androgenic alopecia in 50 males. Efficacy was evaluated by hair pull test, photographic assessment by two blinded dermatologists and videomicroscopic assessment. Efficacy of QR678® and QR678® was more promising in comparison with PRP.[62]

4.9 | Hair transplantation

Hair transplantation is a process of transferring or shifting of hair from hair-bearing areas of the scalp to the bald area.[13] This method is carried out under local anesthesia wherein single sitting transplantation of about 800-1200 grafts would take place.[14] The usual hurdles experienced in females are related to the limited hair donor area and deterioration of the global aspect for the short-term following the transplant.[34] Also, the procedure leads

to temporary/permanent loss of existing hair in the recipient area. Women are often unsatisfied with hair density post-transplant in the recipient areas.[63] Local complications involve postoperative bleeding, scalp erythema, facial edema, crusting, infection, swelling, temporary numbing of the scalp, temporary headaches, and abnormal scarring of the graft.[14]

However, QR678® treatment is performed on an OPD basis with no side effects and with no further disturbance to existing hair. Also, QR678® increases the hair density of existing and new hair.

5 | CONCLUSION

Patterned hair loss is a stressful condition for both the individual as well as professionals. The treatments currently available for the FPHL are only partially efficient and not curative. Intra-dermal injections of QR678® hair growth factor formulation was found to be an effective option for female pattern alopecia with PCOS in our study. This is the first of its kind study using QR678® and QR678 Neo® in PCOS patients. These formulations are not only effective but also beneficial without side effects and easily tolerable by most of the patients. Although the sample size taken was not large, more studies with larger sample size and long-term follow-up are warranted in the future to prove its effectiveness. Also, need to evaluate the mechanisms of action of QR678® and QR678 Neo® in causing hair growth despite hormonal imbalances affecting the hair follicle in FPHL associated with PCOS.

CONFLICT OF INTEREST

The authors of this formulation have been awarded a patent from the United States Patent and Trademark Office (USPTO) and from the Indian Patent Office administered by the Office of the Controller General of Patents, Designs and Trade Marks (CGPDTM) for the invention of this hair formulation, used in this study. None of the authors have a financial interest in any of the products, devices, or drugs mentioned in this article.

AUTHOR CONTRIBUTIONS

Dr Debraj Shome contributed to conceptualization; Dr Rinky Kapoor, Dr Sapna Vadera, and Dr Komal Doshi contributed to manuscript writing; Ghanshyam Patel contributed to statistics.

ORCID

Debraj Shome https://orcid.org/0000-0003-2163-1170

REFERENCES

1. Cruz C, Costa C, Gomes A, Matamá T, Cavaco-Paulo A. Human Hair and the Impact of Cosmetic Procedures: A Review on Cleansing and Shape-Modulating Cosmetics. *Cosmetics*. 2016;3:26.
2. Scalzo K, McKittrick M. Case problem: dietary recommendations to combat obesity, insulin resistance, and other concerns related to polycystic ovary syndrome. *J Am Diet Assoc*. 2000;100:955-957.
3. Cela E, Robertson C, Rush K, et al. Prevalence of polycystic ovaries in women with androgenic alopecia. *Eur J Endocrinol*. 2003;149:439-442.
4. Franks S. Polycystic Ovary Syndrome. *N Engl J Med*. 1995;333(13):853-861.
5. Goodarzi MO, Dumesic DA, Chazenbalk G, Azziz R. Polycystic ovary syndrome: etiology, pathogenesis and diagnosis. *Nat Rev Endocrinol*. 2011;7:219-231.
6. Boyle JA, Cunningham J, O'Dea K, Dunbar T, Norman RJ. Prevalence of polycystic ovary syndrome in a sample of Indigenous women in Darwin, Australia. *Med J Aust*. 2012;196:62-66.
7. Ma YM, Li R, Qiao J, et al. Characteristics of abnormal menstrual cycle and polycystic ovary syndrome in community and hospital populations. *Chin Med J (Engl)*. 2010;123:2185-2189.
8. Gill H, Tiwari P, Dabadghao P. Prevalence of polycystic ovary syndrome in young women from North India: A community-based study. *Indian J Endocrinol Metab*. 2012;16:S389-S392.
9. Joshi B, Mukherjee S, Patil A, Purandare A, Chauhan S, Vaidya R. A cross-sectional study of polycystic ovarian syndrome among adolescent and young girls in Mumbai, India. *Indian J Endocrinol Metab*. 2014;18:317-324.
10. Nidhi R, Padmalatha V, Nagarathna R, Amritanshu R. Prevalence of polycystic ovarian syndrome in Indian adolescents. *J PediatrAdolesc Gynecol*. 2011;24:223-227.
11. Nair MKC, Pappachan P, Balakrishnan S, Leena ML, George B, Russell PS. Menstrual irregularity and poly cystic ovarian syndrome among adolescent girls- a 2 year follow-up study. *Indian J Pediatr*. 2012;9:S69-73.
12. Christodoulopoulou V, Trakakis E, Pergialiotis V, et al. Clinical and Biochemical Characteristics in PCOS Women With Menstrual Abnormalities. *J Fam Reprod Health*. 2016;10:4.
13. Fabbrocini G, Cantelli M, Masarà A, Annunziata MC, Marasca C, Cacciapuoti S. Female pattern hair loss: A clinical, pathophysiologic, and therapeutic review. *Int J Womens Dermatol*. 2018;4:203-211.
14. Dinh QQ, Sinclair R. Female pattern hair loss: Current treatment concepts. *Clin Interv Aging*. 2007;2:189-199.
15. Carmina E, Azziz R, Bergfeld W, et al. Female pattern hair loss and androgen excess: a report from the multidisciplinary androgen excess and PCOS committee. *J Clin Endocrinol Metab*. 2019;104(7):2875-2891.
16. Gainder S, Sharma B. Update on management of polycystic ovarian syndrome for dermatologists. *Indian Dermatol Online J*. 2019;10:97-105.
17. Kapoor R, Shome D. Intradermal injections of a hair growth factor formulation for enhancement of human hair regrowth – safety and efficacy evaluation in a first-in-man pilot clinical study. *J Cosmet Laser Ther*. 2018;20:369-379.
18. ArsieContin L. Male androgenetic alopecia treated with microneedling alone or associated with injectable minoxidil by microinfusion of drugs into the skin. *Surg Cosmet Dermatol*. 2016;8:158-161.
19. Kapoor R, Shome D, Vadera S, Kumar V, Ram MS. QR678 & QR678 Neo Hair Growth Formulations: A Cellular Toxicity & Animal Efficacy Study. *Plast Reconstr Surg Global Open*. 2020;8(2843):1-13. https://journals.lww.com/prsgo/Abstract/9000/QR678___QR678_Neo_Hair_Growth_Formulations__A.97136.aspx
20. National Institutes of Health. Evidence-based methodology workshop on polycystic ovary syndrome, 2012. Executive summary.
21. Fauser BCJM, Tarlatzis BC, Rebar RW, et al. Consensus on women's health aspects of polycystic ovary syndrome (PCOS): The Amsterdam ESHRE/ASRM- Sponsored 3rd PCOS Consensus Workshop Group. *Fertil Steril*. 2012;97(1):28-38.e25.
22. Hunt N, McHale S. The psychological impact of alopecia. *BMJ*. 2005;331:951-953.
23. Poretsky L, Cataldo NA, Rosenwaks Z, Giudice LC. The insulin-related ovarian regulatory system in health and disease. *Endocr Rev*. 1999;20:535-582.
24. Tsilchorozidou T, Overton C, Conway GS. The pathophysiology of polycystic ovary syndrome. *Clin Endocrinol*. 2004;60:1-17.

25. Harwood K, Vuguin P, DiMartino-Nardi J. Current approaches to the diagnosis and treatment of polycystic ovarian syndrome in youth. *Horm Res*. 2007;68:209-217.
26. Huang A, Brennan K, Azziz R. Prevalence of hyperandrogenemia in the polycystic ovary syndrome diagnosed by the National Institutes of Health 1990 criteria. *FertilSteril*. 2010;93:1938-1941.
27. Lobo RA. *Infertility, Contraception, and Reproductive Endocrinology*, 3rd edn. Cambridge, UK: (Blackwell Scientific Publications; 1991;447-487.
28. Olsen EA. Female pattern hair loss. *J Am Acad Dermatol*. 2002;45:S70-80.
29. Etcoff N. *Survival of the Prettiest: The Science of Beauty*. New York, NY: Doubleday; 1999.
30. Goldberg LJ, Lenzy Y. Nutrition and hair. *Clin Dermatol*. 2010;28:412-419.
31. Finner AM. Nutrition and hair: Deficiencies and supplements. *Dermatol Clin*. 2013;31:167-172.
32. Guo EL, Katta R. Diet and hair loss: Effects of nutrient deficiency and supplement use. *Dermatol Pract Concept*. 2017;7:1-10.
33. Blumeyer A, Tosti A, Messenger A, et al. Evidence-based guideline for the treatment of androgenetic alopecia in women and in men. *J Dtsch Dermatol Ges*. 2011;9:S1-57.
34. Herskovitz I, Tosti A. Female pattern hair loss. *Int J Endocrinol Metab*. 2013;11(4):e9860.
35. Varothai S, Bergfeld WF. Androgenetic alopecia: An evidence-based treatment update. *Am J Clin Dermatol*. 2014;15:217-230.
36. Friedman ES, Friedman PM, Cohen DE. Allergic contact dermatitis to topical minoxidil solution: etiology and treatment. *J Am Acad Dermatol*. 2002;46:309-312.
37. Blume-Peytavi U, Hillmann K, Dietz E, Canfield D, Garcia Bartels N. A randomized, single-blind trial of 5% minoxidil foam once daily versus 2% minoxidil solution twice daily in the treatment of androgenetic alopecia in women. *J Am Acad Dermatol*. 2010;65:6.
38. Suchonwanit P, Thammarucha S, Leerunyakul K. Minoxidil and its use in hair disorders: a review. *Drug Design Dev Ther*. 2019;13:2777-2786.
39. Adil A, Godwin M. The effectiveness of treatments for androgenetic alopecia: a systematic review and meta-analysis. *J Am Acad Dermatol*. 2017;77(1):136-141.e5.
40. American Academy of Pediatrics Committee on Drugs. The transfer of drugs and other chemicals into human milk. *Pediatrics*. 2001;108:776-789.
41. Sinclair RD. Female pattern hair loss: a pilot study investigating combination therapy with low-dose oral minoxidil and spironolactone. *Int J Dermatol*. 2018;57:104-109.
42. Hajheydari Z, Akbari J, Saeedi M, Shokoohi L. Comparing the therapeutic effects of finasteride gel and tablet in treatment of the androgenetic alopecia. *Indian J Dermatol Venereol Leprol*. 2009;75:47-51.
43. Iorizzo M, Vincenzi C, Voudouris S, Piraccini BM, Tosti A. Finasteride treatment of female pattern hair loss. *Arch Dermatol*. 2006;142:298-302.
44. Olsen EA, Hordinsky M, Whiting D, et al. Dutasteride Alopecia Research Team. The importance of dual 5alpha-reductase inhibition in the treatment of male pattern hair loss: results of a randomized placebo- controlled study of dutasteride versus finsteride. *J Am Acad Dermatol*. 2006;55:1014-1023.
45. Camacho F, Tosti A. Medical treatment of female alopecia. *Monogr Dermatol*. 2005;18(92):59.
46. Hamblin MR, Demidova TN, eds. Mechanisms of low level light therapy. Biomedical optics. 2006.
47. Avram MR, Leonard RT Jr, Epstein ES, Williams JL, Bauman AJ. The current role of laser/light sources in the treatment of male and female pattern hair loss. *J Cosmet Laser Ther*. 2007;9:27-28.
48. Leavitt M, Charles G, Heyman E, Michaels D. HairMax LaserComb laser phototherapy device in the treatment of male androgenetic alopecia: A randomized, double-blind, sham device-controlled multicenter trial. *Clin Drug Investig*. 2009;29:283-292.
49. Yazdabadi A, Green J, Sinclair R. Successful treatment of female-pattern hair loss with spironolactone in a 9-year-old girl. *Australas J Dermatol*. 2009;50:113-114.
50. Adamopoulos DA, Karamertzanis M, Nicopoulou S, Gregoriou A. Beneficial effect of spironolactone on androgenic alopecia. *Clin Endocrinol (Oxf)*. 1997;47:759-760.
51. Burke BM, Cunliffe WJ. Oral spironolactone therapy for female patients with acne, hirsutism or androgenic alopecia. *Br J Dermatol*. 1985;112:124-125.
52. Sinclair R, Wewerinke M, Jolley D. Treatment of female pattern hair loss with oral antiandrogens. *Br J Dermatol*. 2005;152:466-473.
53. Levy LL, Emer JJ. Female pattern alopecia: current perspectives. *Int J Women's Health*. 2013;5:541-556.
54. Simard J, Luthy I, Guay J, Bélanger A, Labrie F. Characteristics of interaction of the antiandrogenflutamide with the androgen receptor in various target tissues. *Mol Cell Endocrinol*. 1986;44:261-270.
55. Paradisi R, Porcu E, Fabbri R, Seracchioli R, Battaglia C, Venturoli S. Prospective cohort study on the effects and tolerability of flutamide in patients with female pattern hair loss. *Ann Pharmacother*. 2011;45(469–75):52.
56. Bruni V, Peruzzi E, Dei M, et al. Hepatotoxicity with low- and ultralow-dose flutamide: a surveillance study on 203 hyperandrogenic young females. *Fertil Steril*. 2012;98:1047-1052.
57. Dhurat R, Sukesh MS, Avhad G, Dandale A, Pal A, Pund P. A randomized evaluator blinded study of effect of microneedling in androgenetic alopecia: a pilot study. *Int J Trichol*. 2013;5:6-11.
58. Dhurat R, Mathapati S. Response to microneedling treatment in men with androgenetic alopecia who failed to respond to conventional therapy. *Indian J Dermatol*. 2015;60:260-263.
59. Kiichiro Y, Brown LF, Michael D. Control of hair growth & follicle size by VEGF-mediated angiogenesis. *J Clin Invest*. 2001;107:409-417.
60. Kozlowska U, Blume-Peytavi U, Kodelja V, et al. Expression of vascular endothelial growth factor (VEGF) in various compartments of the human hair follicle. *Arch Dermatol Res*. 1998;290:661-668.
61. Danilenko DM, Ring BD, Yanagihara D, et al. Keratinocyte growth factor is an important endogenous mediator of hair follicle growth, development, & differentiation. Normalization of the nu/nu follicular differentiation defect & amelioration of chemotherapy-induced alopecia. *Am J Pathol*. 1995;147:145-154.
62. Kapoor R, Shome D, Vadera S, Ram S. QR678 & QR678 Neo Vs PRP-A randomized, comparative, prospective study. *J Cosmet Dermatol*. 2020;00:1-9.
63. Unger WP, Unger RH. Hair transplanting: An important but often forgotten treatment for female pattern hair loss. *J Am Acad Dermatol*. 2001;49:5.

How to cite this article: Kapoor R, Shome D, Doshi K, Patel G, Vadera S. Evaluation of efficacy of QR 678 and QR678 neo hair growth factor formulation for the treatment of female pattern alopecia in patients with PCOS—A prospective study. *J Cosmet Dermatol*. 2020;00:1–10. https://doi.org/10.1111/jocd.13673